

Combined manual reading and computer-aided quantitative analysis for the standardization of HER2 IHC scoring

Alma J Sanchez-Salazar, MD¹, Ruben Alvarado, BSc, MBA¹, Rabiul Ibraheem, BSc¹, Cristina Steele, MBA, CG(ASCP)², Dan Walker, BA³, Yael Glickman, PhD²

¹ CorePath Laboratories, San Antonio, TX, USA; ² Applied Spectral Imaging, Carlsbad, CA, USA; ³ Motic Digital Pathology, Emeryville, CA, USA

Disclosures: AJSS, RA and RI have no disclosure, CS and YG are employees of Applied Spectral Imaging, DW is an employee of Motic Digital Pathology

Background & Introduction

- Computer-aided image analyses are gaining growing adoption, particularly when seamlessly integrated in the digital pathology workflow.
- These computerized methods, when combined with manual reading, have been shown to help standardize the reporting of IHC specimens¹, specially in cases where the tumor has variable intensity of expression.
- The aim of this evaluation is to further assess the usefulness of computer-aided quantitative analysis when integrated in the laboratory workflow, focusing on its role as a second opinion for the standardization of HER2 IHC scoring on breast cancer cases.

Design & Methods

- Five slides prepared for each breast cancer core biopsy specimen were stained with H&E, ER, PR, Ki67 and HER2.
- All slides were scanned with MoticEasyScan Infinity (Motic Digital Pathology) at 40X (0.26 um/px) and saved in SVS format. They were examined by certified pathologists using both conventional microscopy and digital imaging. HER2 FISH was requested to complete the evaluation of equivocal HER2 IHC cases.
- HER2 IHC images were further analyzed using the HiPath Pro scanner-agnostic software (Applied Spectral Imaging). Regions of interest marked on the H&E images were automatically transferred to HER2 specimens following tissue matching. Cells automatically identified as tumor cells were segmented and classified using a color-coded overlay.
- Computerized results were compared to manual readings. In case of discrepancy, a second manual reading was performed.

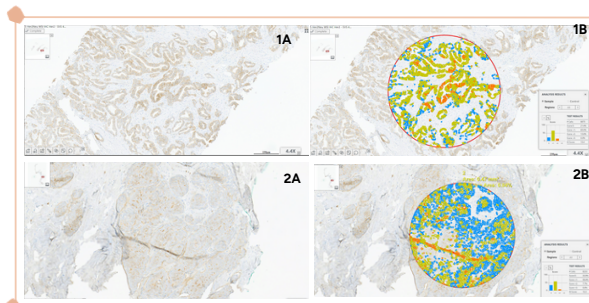


Figure 1: Representative examples of concordant HER2 case #5 (1) and discordant HER2 case #8 (2) featuring IHC staining (A) and computer-aided analysis (B)

Case #	ER	PR	Ki67	HER2 Read 1	HER2 Aided	HER2 Read 2	HER2 FISH
1	+	+	<14%	2+	2+		NEG
2	-	-	≥14%	0	0		
3	+	+	<14%	0	1+	1+	
4	+	+	≥14%	2+	2+		NEG
5	+	+	≥14%	2+	2+		NEG
6	+	-	≥14%	3+	3+		
7	+	+	≥14%	0	0		
8	+	+	≥14%	2+	1+	2+	NEG
9	+	+	≥14%	3+	No focus		
10	+	+	≥14%	2+	3+	3+	POS
11	-	-	≥14%	0	1+	1+	
12	+	+	≥14%	1+	1+		
13	+	+	<14%	0	0		
14	-	-	≥14%	0	0		
15	+	+	≥14%	1+	0	1+	
16	+	+	≥14%	3+	2+	3+	
17	-	+	≥14%	2+	2+		POS
18	-	-	≥14%	2+	2+		POS
19	+	+	≥14%	0	0		
20	-	-	≥14%	3+	3+		

Table 1: IHC profile of study cases including manual reading of ER, PR, Ki67 and HER2 (reading 1 and repeated reading 2 for discrepant cases), as well as computer-aided HER2 IHC scoring. HER2 FISH results are provided for all equivocal cases.

Results

- Twenty biopsy specimens from 20 patients were included in this evaluation. 19 samples had a diagnosis of invasive ductal or lobular carcinoma, and one of metaplastic carcinoma with chondroid differentiation.
- The ER, PR, Ki67 and HER2 IHC profiles of the cases are detailed in Table 1. As shown in this Table, the first manual reading of HER2 IHC diagnosed 4 cases as positive (3+), 9 as negative (0 or 1+) and 7 as equivocal (2+). FISH was performed on all equivocal cases, confirming 3 as HER2 positive and 4 as HER2 negative.
- Computer-aided HER2 scoring was obtained for 19 out of 20 images as one image out of focus was removed from analysis. Concordance with first manual reading was observed in 13 cases.
- During second manual reading following computerized analysis, two cases scored as HER2 (0) were re-scored as HER2 (1+), matching software assessment. A third case diagnosed as equivocal (2+) was re-scored as (3+) following the review of the computerized analysis. This case was later confirmed as FISH positive.
- The diagnosis of the remaining 3 cases was unchanged after review of computerized results.

Conclusions

- This evaluation exemplifies the potential usefulness of computer-aided scoring as second opinion when reporting HER2 IHC in breast cancer, particularly in cases of low HER2 expression.
- This further illustrates that the combined use of manual reading and computerized analysis may help standardize IHC assessment and potentially reduce inter-observer variability.



Scan for poster reference